



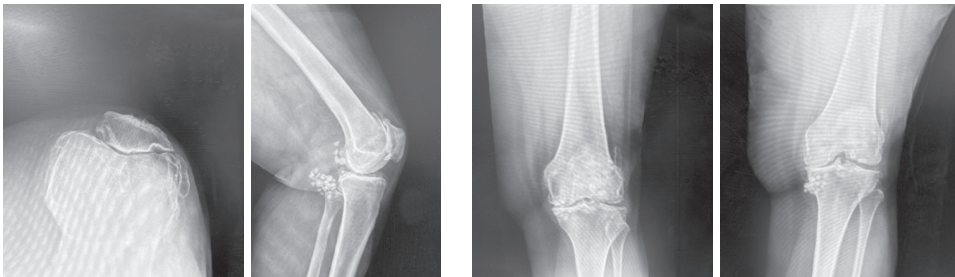
# Mako Total Knee 2.0

► Case review with Kirby Hitt, M.D.

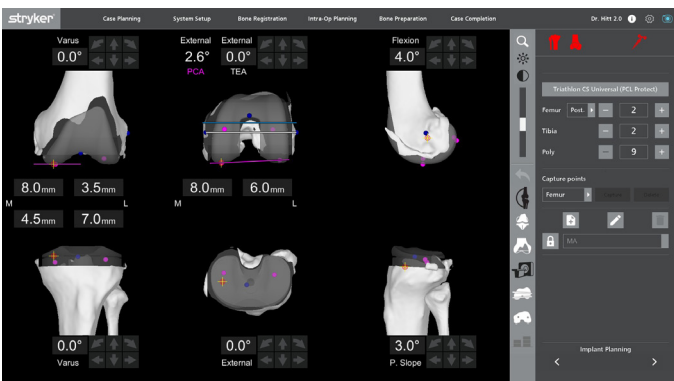


## Patient history / Pre-op x-rays

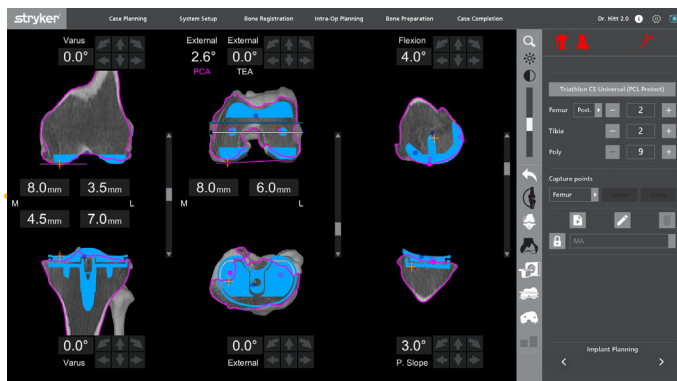
- 69-year-old female
- BMI 34



## 3D CT-based pre-planning

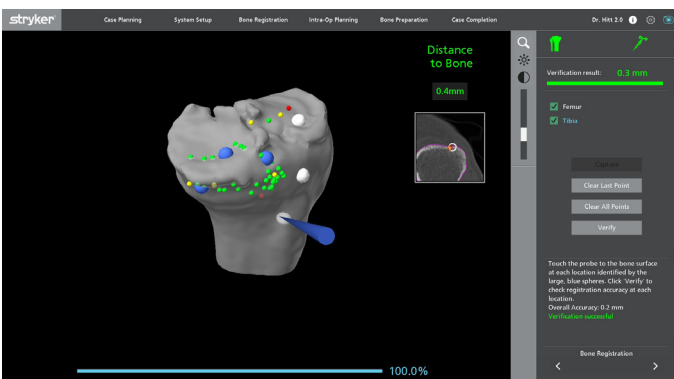


The 3D CT-based pre-plan demonstrates that the operative knee is in varus, set to the default planning parameters and planned component sizes are 2 femur and 2 tibia with the Triathlon Knee System.



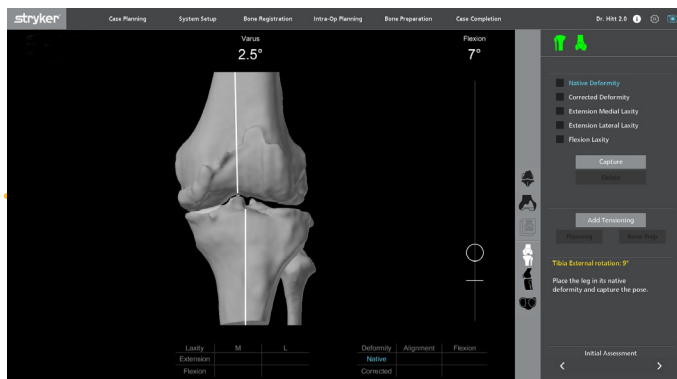
In CT view, the surgeon assesses the concentricity of the medial femoral condyle in the sagittal plane and trochlea congruity in the transverse plane.

## Bone registration



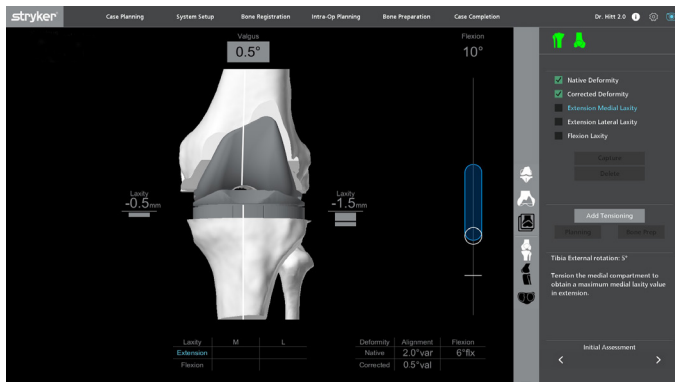
Bone registration is complete, and the plan is verified within 0.5 millimeters of the CT scan.

## Native deformity



The surgeon holds the leg in extension to evaluate the limb's coronal and sagittal alignments. The software captures the native deformity, which shows a 6° flexion contracture and a 2.0° varus deformity.

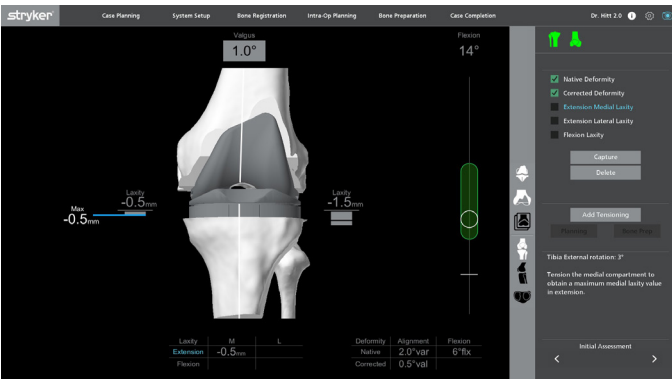
## Corrective deformity



The surgeon then applies a corrective stress to the knee and captures the corrected deformity. This knee swings into valgus and corrects to 0.5° of valgus.

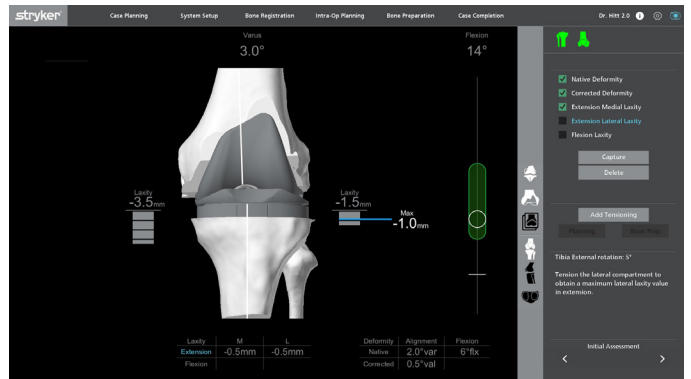
## Extension medial assessment

Utilizing the digital tensioner, the surgeon can capture each compartment in flexion and extension independently of each other. The digital tensioner also provides audible and visual cues, every 0.5mm that the selected compartment opens. The surgeon uses these cues to find the ligament end stop. The maximum amount of laxity that can be achieved will be automatically stored in the system and then captured. For the extension poses, the surgeon starts by bringing the knee into extension and relaxes the posterior capsule.



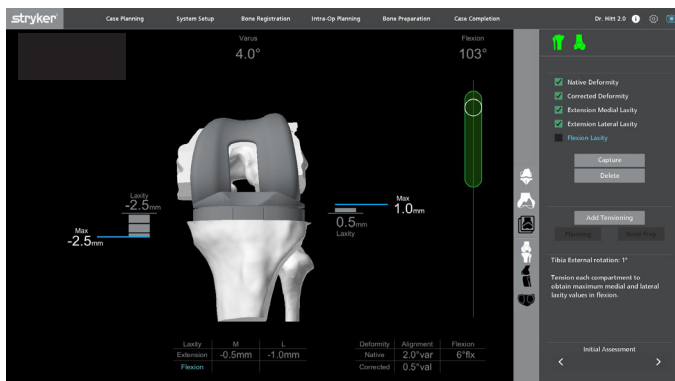
The surgeon then applies a valgus stress to open up the medial compartment in extension. Using the audible and visible cues, the maximum ligament laxity of -0.5mm is stored and captured in the laxity table.

## Extension lateral assessment



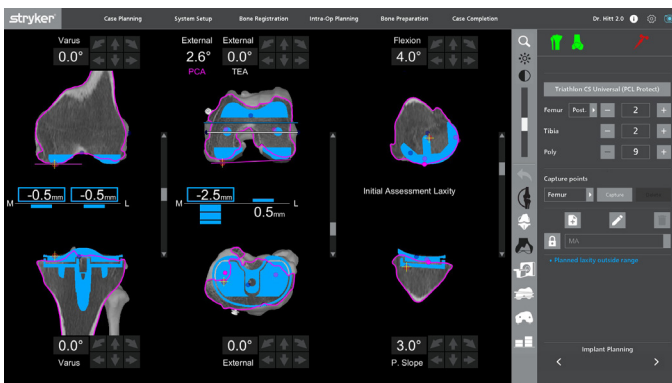
Similarly on the lateral side, the surgeon applies a varus stress to open up the lateral compartment and will capture the maximum laxity value which is also -0.5mm.

## Flexion medial and lateral assessment

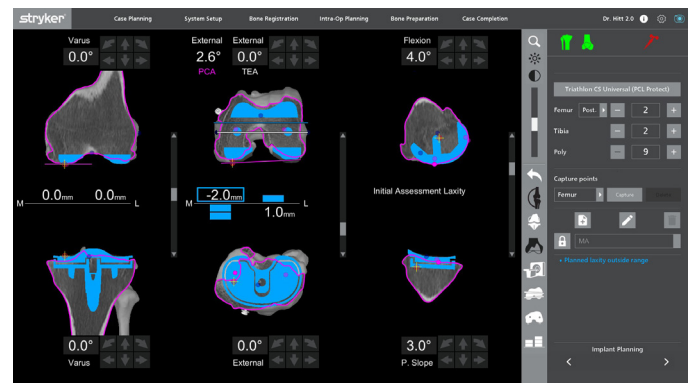


In flexion, the surgeon chooses to assess both the medial and lateral compartments together by applying tension to the joint, using the Mako spacer paddles. This results in asymmetric laxities, and these values are captured in the laxity table.

## Intraoperative planning



Starting in extension, the medial and lateral laxities are each -0.5mm tight. In order to loosen this up, the surgeon anchors centrally and moves the tibia resection 0.5mm distal. This results in symmetric laxity values in extension, balanced at 0mm. Refer to next step.

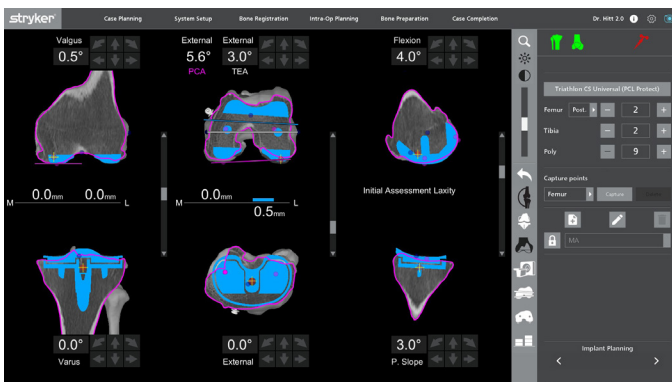


The surgeon also completes the following implant adjustments to balance the knee.

- Anchor centrally on the femur in the transverse plane and externally rotate 2.5° to increase the medial flexion laxity.
- Anchor medially on the femur in the coronal plane, and add 0.5° of valgus.
- Anchor laterally on the femur in the transverse plane, and add 0.5° of external rotation.

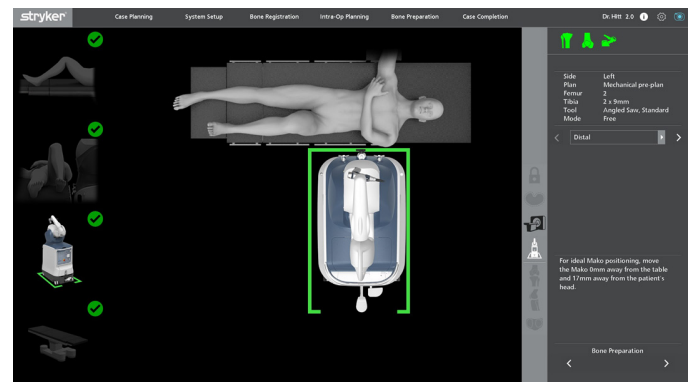
Refer to the next step for the final implant plan, with all component adjustments completed before executing bone preparation.

## Final implant plan



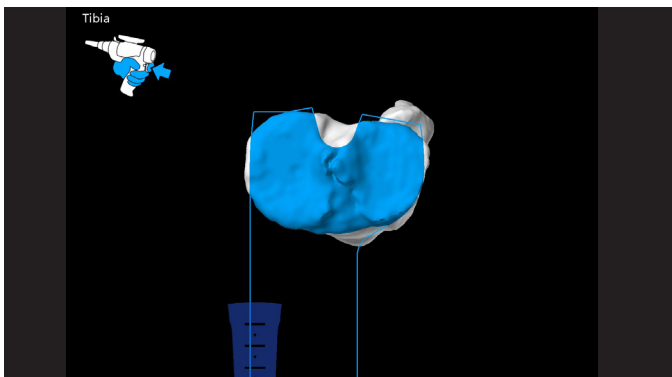
These adjustments balance the knee in flexion and extension while maintaining medial femoral stability in the sagittal plane, trochlea congruity and posterior condylar offset. The surgeon plans the laxities to 0mm, knowing that the knee will naturally open up 0.5mm to 1.0mm throughout the procedure, resulting in 0.5mm to 1.0mm laxities at the end of the case.

## Mako Park



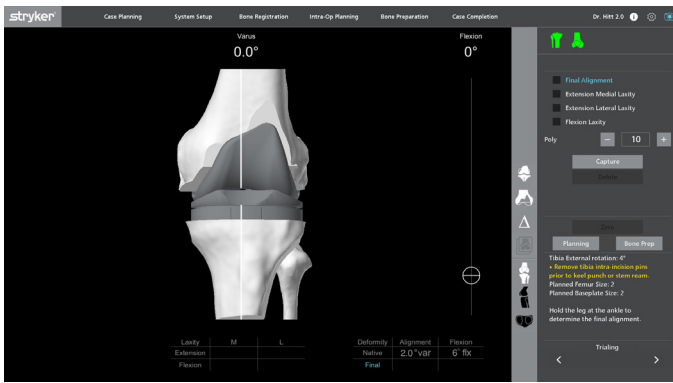
Mako Park is used to provide guidance on positioning the patient anatomy and the Mako System.

## AccuStop™ haptic technology

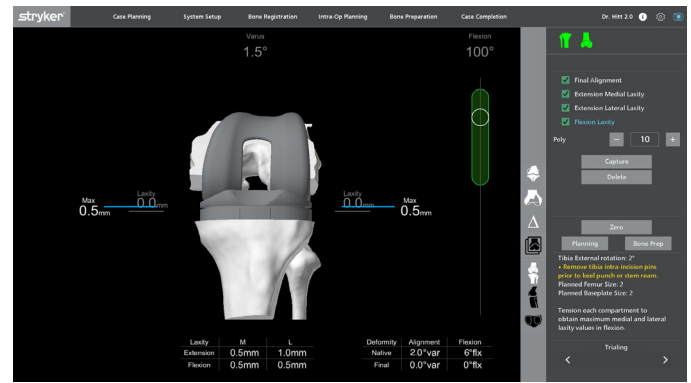


The surgeon completes bone preparation using AccuStop haptic technology. The saw is constrained in the virtual boundary that is established by the surgeon's patient specific plan. By double clicking the MICS trigger, the surgeon can advance through their cut sequence on their own.

## Trialing



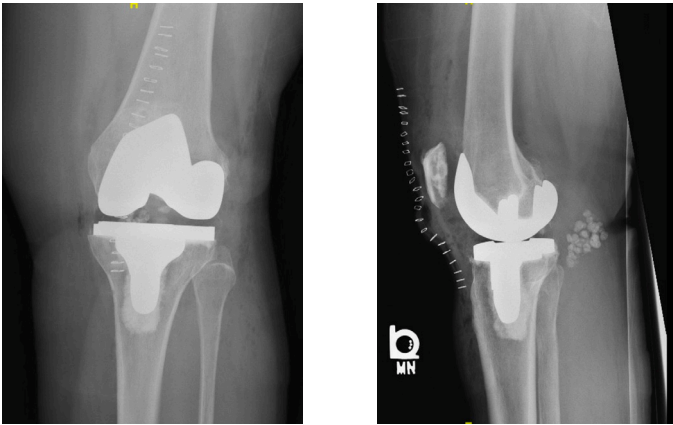
14



15

Once bone prep is complete, and the trials are inserted, the surgeon will advance to the trialing page. On the trialing page, the surgeon will capture the final alignment and the final extension and flexion laxities. The trialing assessment demonstrates that the limb is capable of reaching full extension. The native varus deformity is corrected from 2.0° to 0° varus. The extension and flexion laxities are all balanced within 1.0mm, as planned.

## Post-op x-rays



16

## Learn more about Mako Total Knee SmartRobotics™



Dr. Hitt is a paid consultant of Stryker Orthopaedics. The opinions expressed by Dr. Hitt are those of Dr. Hitt and not necessarily those of Stryker. Individual experiences may vary. A surgeon must always rely on his or her own professional clinical judgment when deciding whether to use a particular product when treating a particular patient. Stryker does not dispense medical advice and recommends that surgeons be trained in the use of any particular product before using it in surgery.

The information presented is intended to demonstrate the breadth of Stryker's product offerings. A surgeon must always refer to the package insert, product label and/or instructions for use before using any of Stryker's products. Products may not be available in all markets because product availability is subject to the regulatory and/or medical practices in individual markets. Please contact your sales representative if you have questions about the availability of products in your area.

Stryker Corporation or its divisions or other corporate affiliated entities own, use or have applied for the following trademarks or service marks: AccuStop, Mako, SmartRobotics, Stryker, Triathlon. All other trademarks are trademarks of their respective owners or holders.

JR-MTKA-STUD-951642  
Copyright © 2024 Stryker