

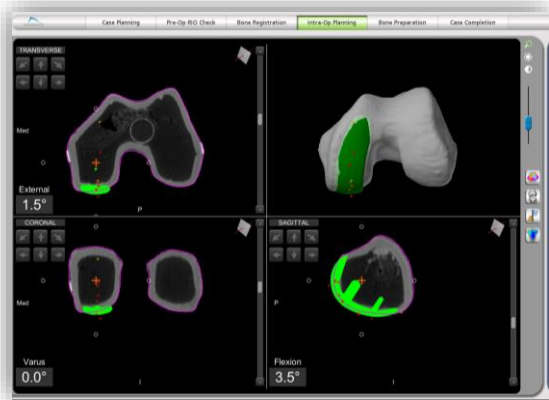


Mako Partial Knee SmartRobotics™

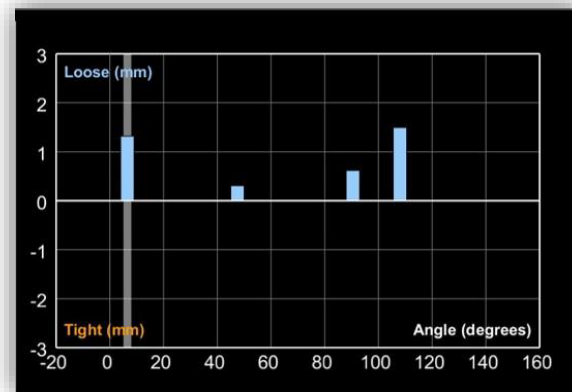
Three core features

Mako Partial Knee

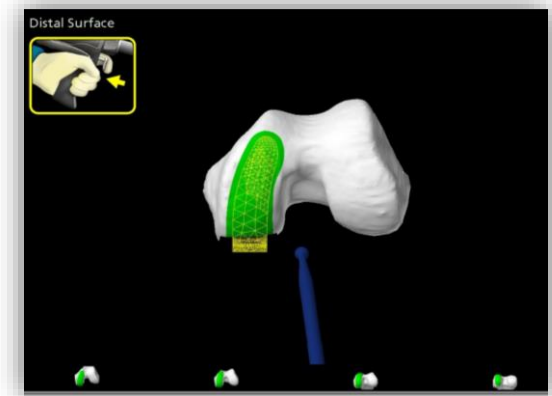
CT-based planning



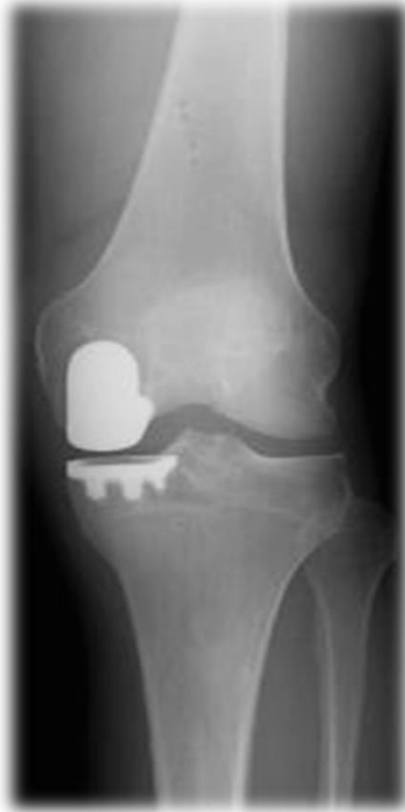Dynamic joint balancing



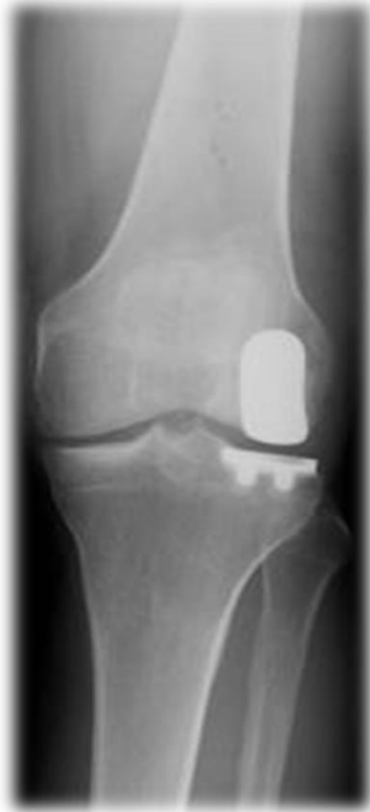AccuStop™ haptic technology



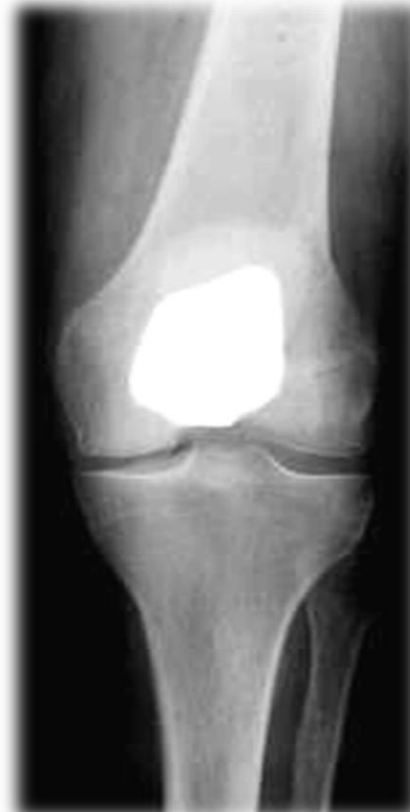Partial Knee indications



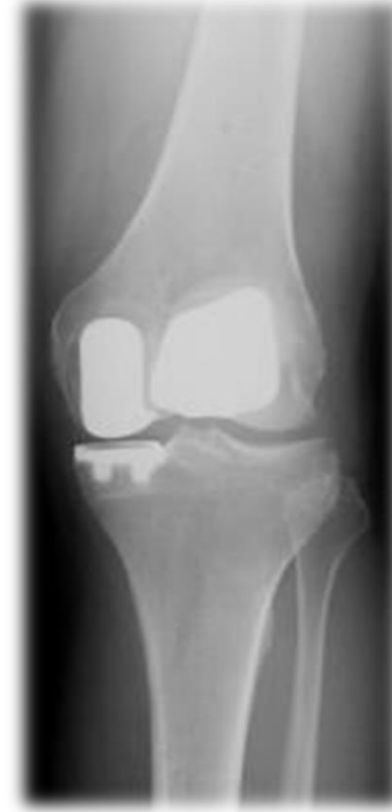Medial



Lateral

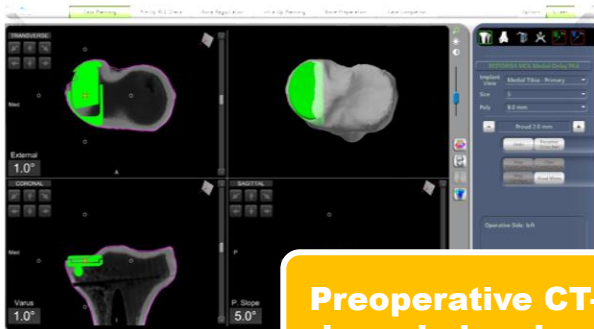


Patellofemoral

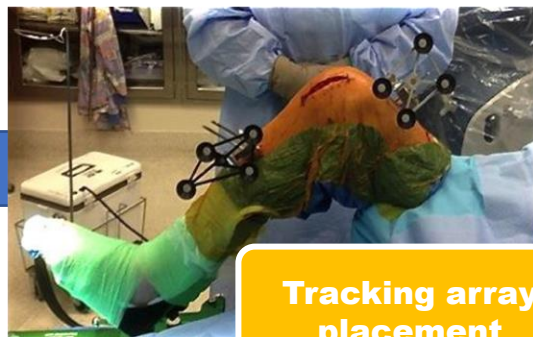


**Medial
Bicompartamental**

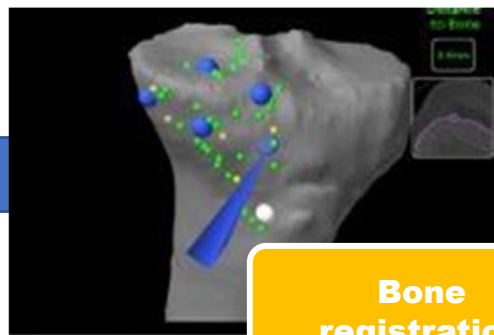
Mako Partial Knee Workflow



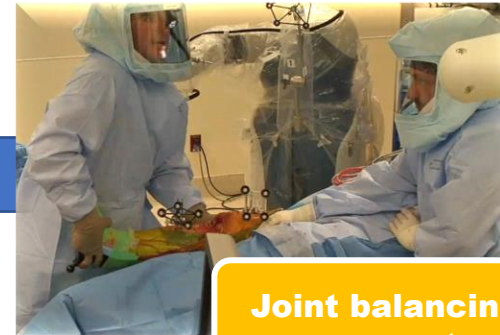Preoperative CT-based planning



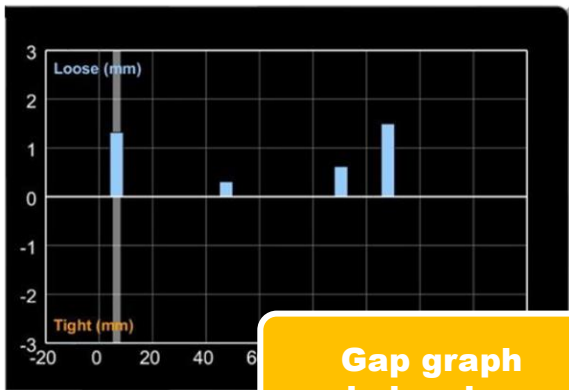
Tracking array placement



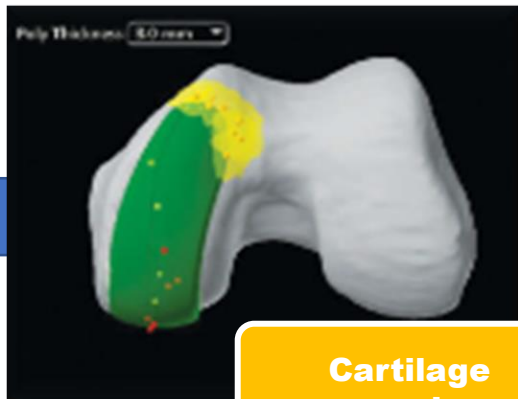Bone registration



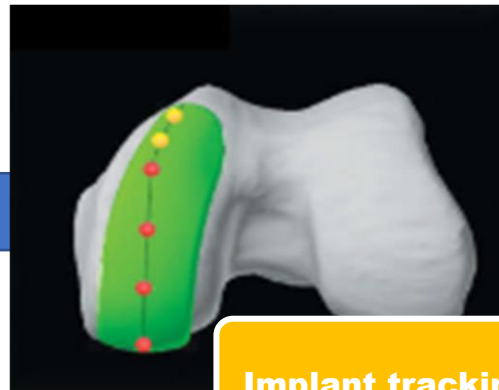
Joint balancing – pose capture



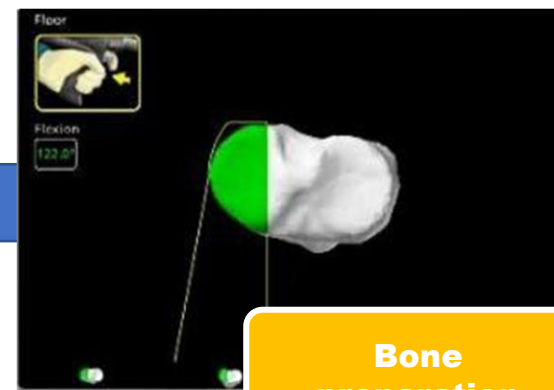
Gap graph balancing



Cartilage mapping



Implant tracking

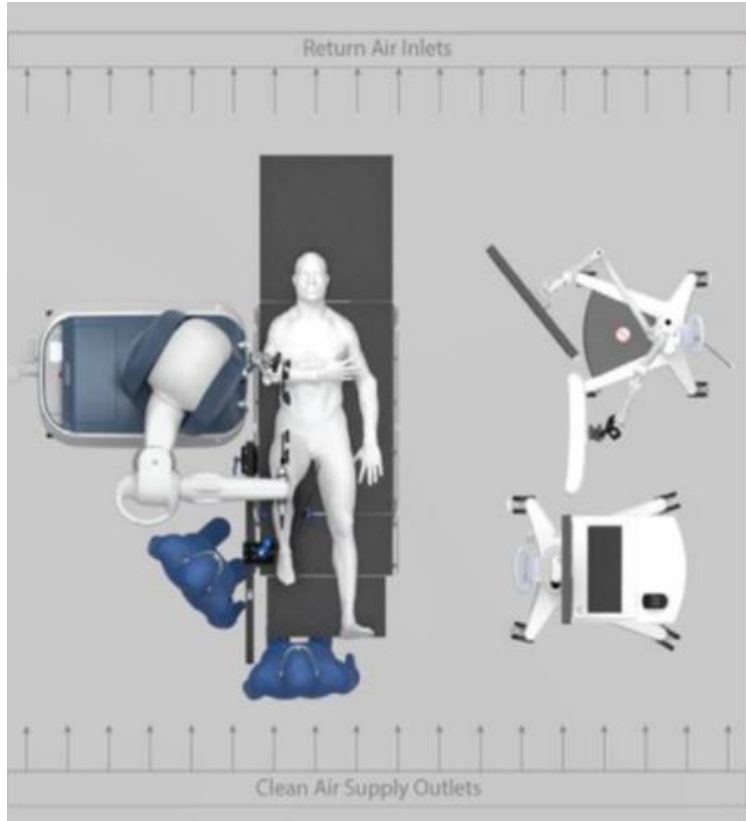


Bone preparation

Setup

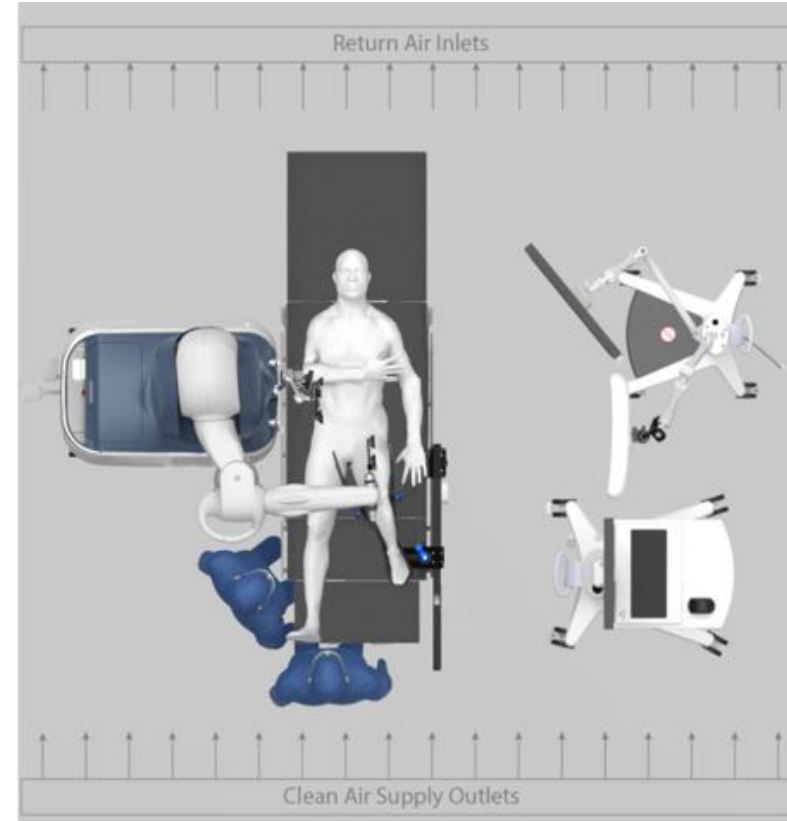
**Mako Partial Knee
SmartRobotics™**

Patient positioning



Planar workflow

Mako robotic-arm **must be on the operative side.**



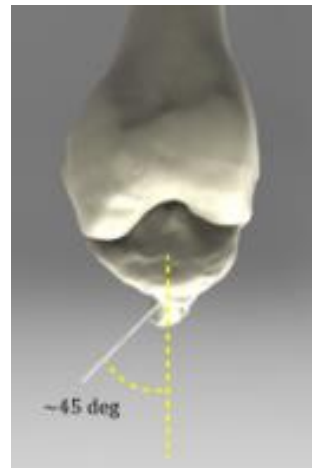
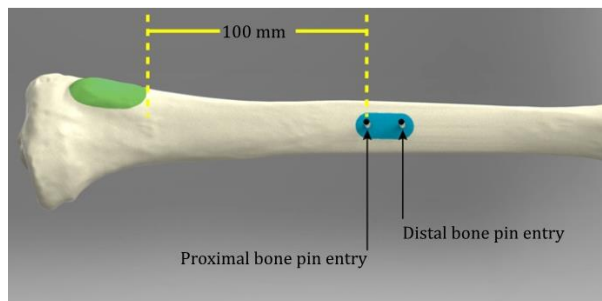
Burr only workflow

Mako robotic-arm **can be on the operative or non-operative side.**

Pin placement

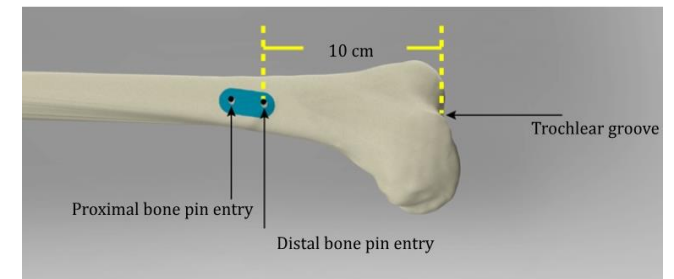
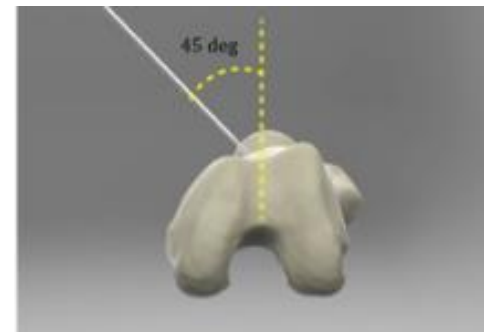
Tibia

- Surgeon makes incision a minimum of 10 cm (approximately four fingerbreadths) inferior to the tibial tubercle and 10-15 mm medial to the tibial crest
- Surgeon makes second incision approximately 15 mm distal to previous incision or uses array stabilizer as guide
- Ensure array stabilizer used corresponds to the correct pin diameter (i.e. 3.2 mm bone pins used with 3.2 mm array stabilizer)
- Pins should be angled perpendicular to bone surface, approximately 45 degrees from the sagittal midline piercing both cortices
- Array stabilizer should be fully seated so that the barrels are in the bone surface



Femur

- Patient knee should be flexed to >90 degrees to elongate quadriceps muscles
- Surgeon makes first incision approximately 10 cm (approximately 3-4 fingerbreadths) proximal to the superior edge of the patella and approximately 45 degrees medial to the sagittal midline
- Surgeon makes second incision approximately 15 mm proximal to previous incision or uses array stabilizer as guide
- Surgeon drives bone pins piercing both cortices
- Array stabilizer should be fully seated so that the barrels are on the bone surface



Array placement

- A sterile staff member assembles the pelvic array adapter and 2-pin clamp
- The clamp slides over the pins with the clamp against the top of the array stabilizer
- The clamp's screw should point away from the camera and the pelvic array adaptor's screw away from the incision
- The knee femoral and tibial arrays are attached to the pelvic array adaptors
- The arrays should be parallel to each other and the camera in the sagittal plane
- Using the square driver, tighten the screws in this order:
 - Array screws
 - Pelvic array adapter screw
 - Clamp screw

Tibial array **Femoral array**



Shown above: Array assembly
(left knee)



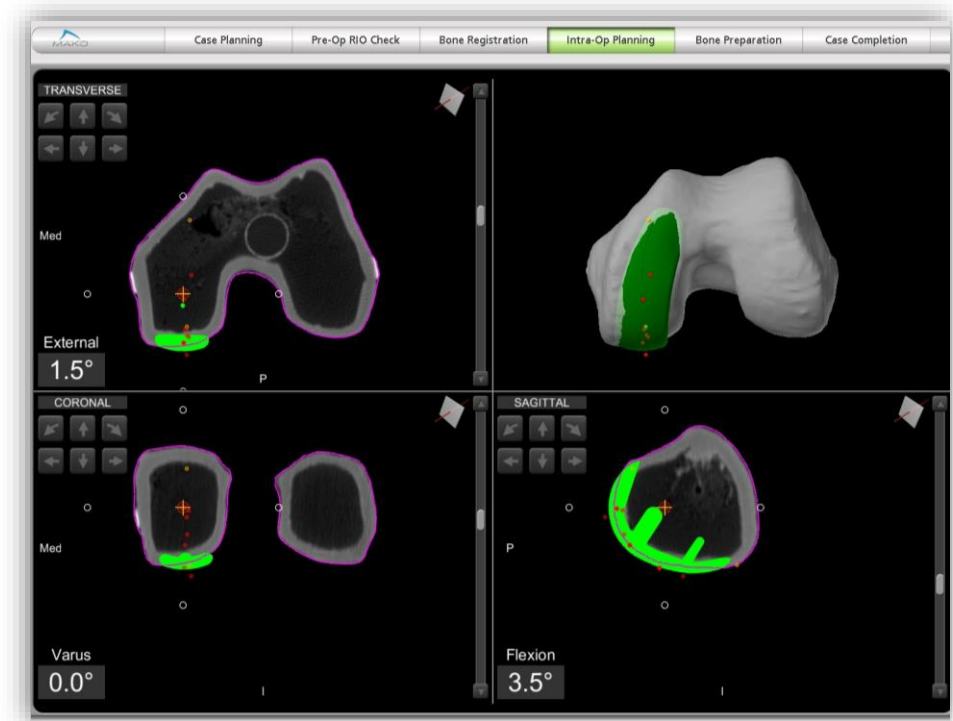
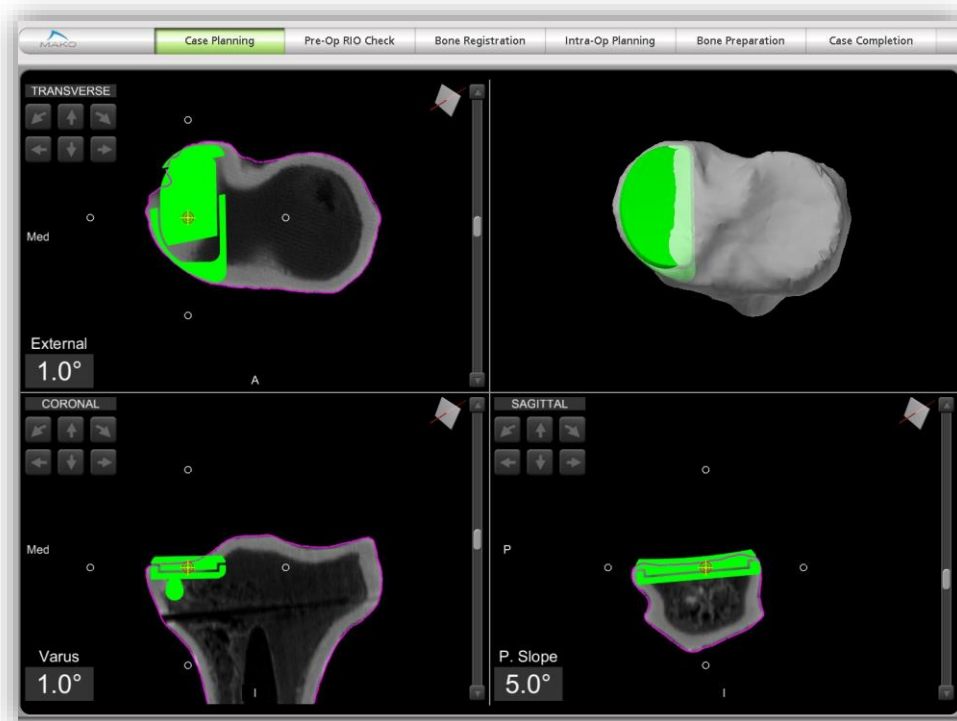
3D CT-based planning

**Mako Partial Knee
SmartRobotics™**

Know more.

CT-based planning

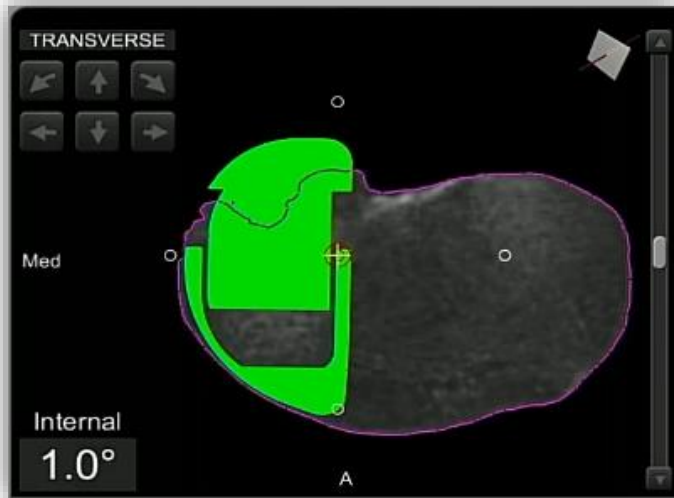
CT data is segmented to create a 3D model of the patient's bony anatomy. The Mako Partial Knee application allows a surgeon to manipulate the unicompartamental implant on the patient's virtual 3D anatomy during preoperative planning.



CT-based planning

Tibial positioning

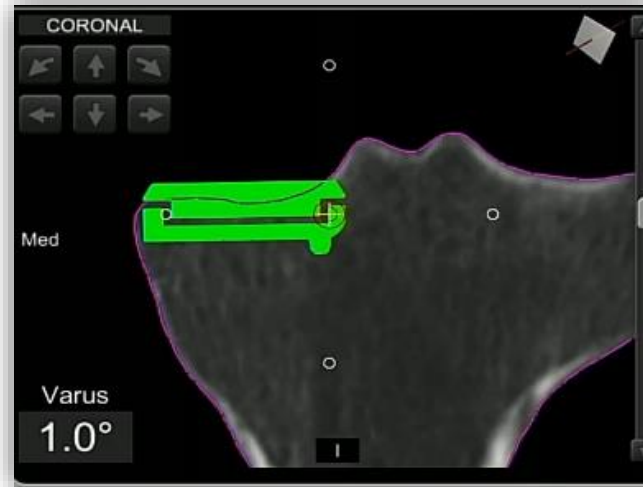
Transverse



Check implant is:

- ✓ Following natural curvature of bone
- ✓ Not overhanging past native bone

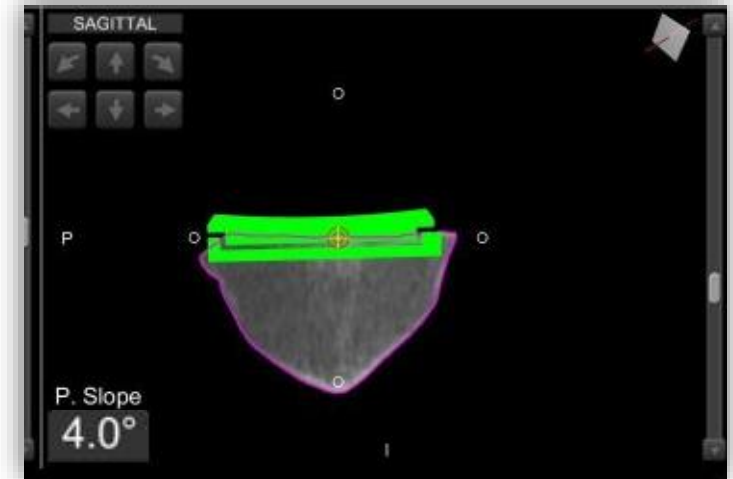
Coronal



Check implant is:

- ✓ Not overhanging past native bone medially
- ✓ Not impeding on tibial eminence

Sagittal



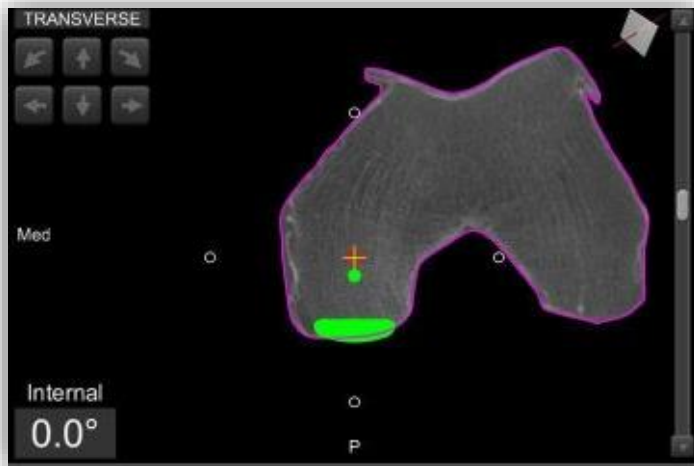
Check implant is:

- ✓ 2.5 – 3.5 mm proud
- ✓ Following patient's native slope

CT-based planning

Femoral positioning

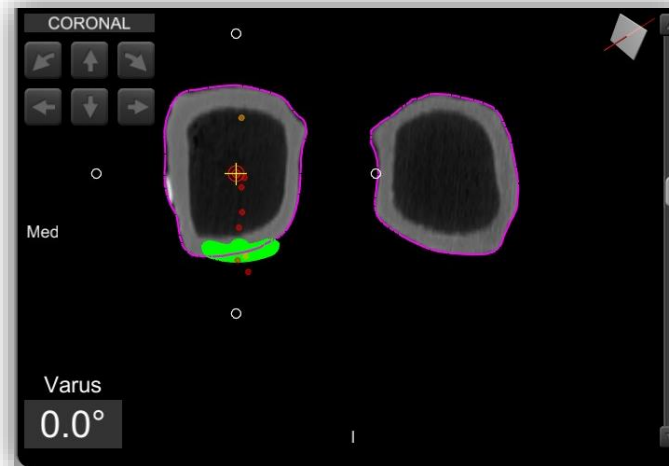
Transverse



Check implant is:

- ✓ Lateralized without overhanging into notch

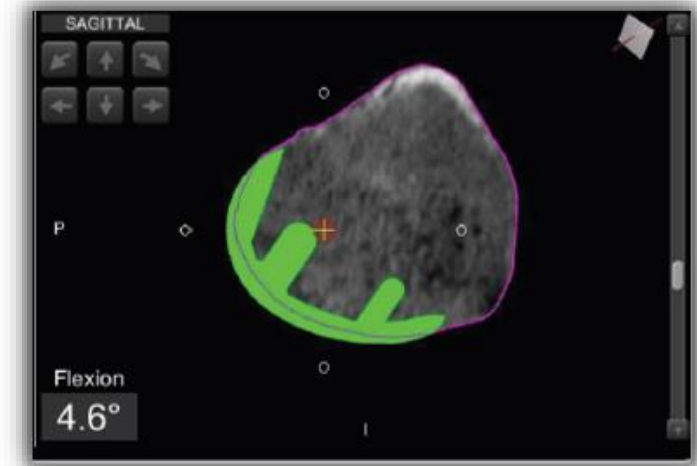
Coronal



Check implant is:

- ✓ Following curvature of patient's native bone

Sagittal



Check implant is:

- ✓ 1mm proud posteriorly and distally
- ✓ Anterior and posterior tips are not overhanging or notching

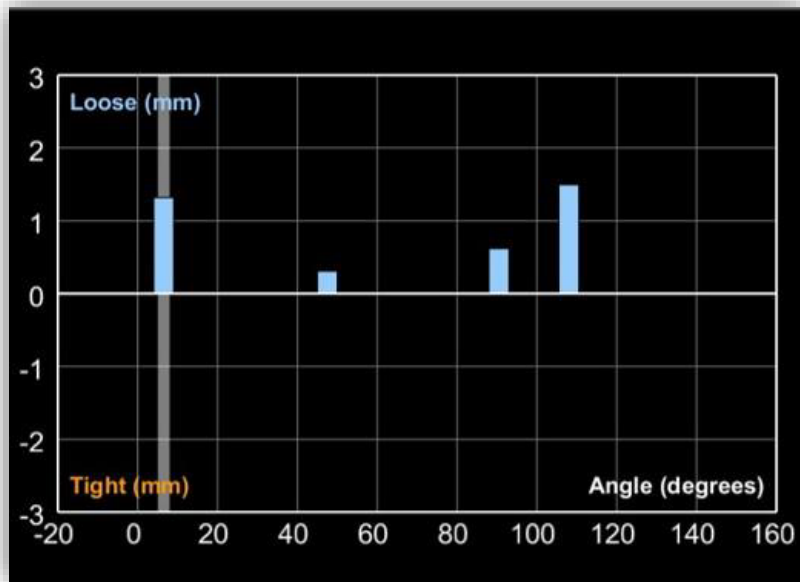
Dynamic Joint Balancing

**Mako Partial Knee
SmartRobotics™**

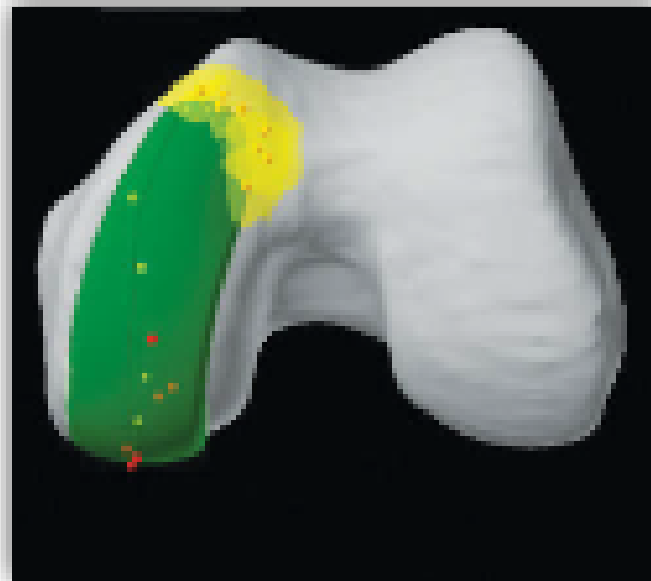Know more.

Dynamic joint balancing

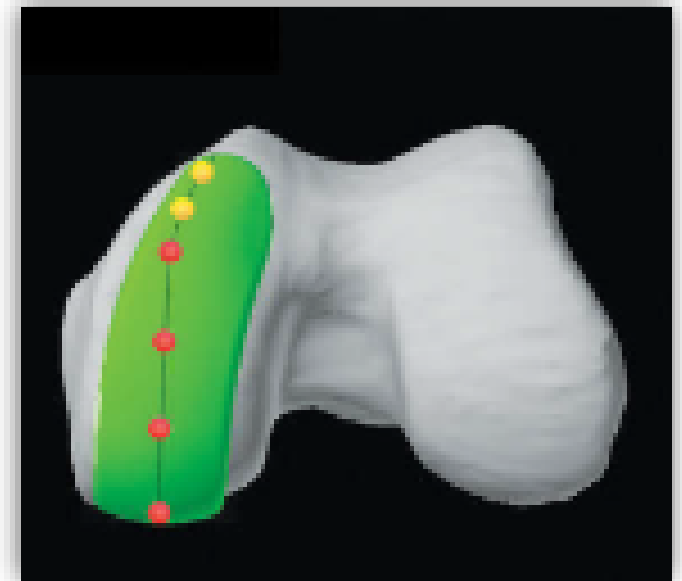After assessing the patient's ligament tension, gap analysis, limb alignment and cartilage transition zones, surgeon-controlled intraoperative adjustments can be made to the preoperative plan.



Gap balancing



Cartilage mapping

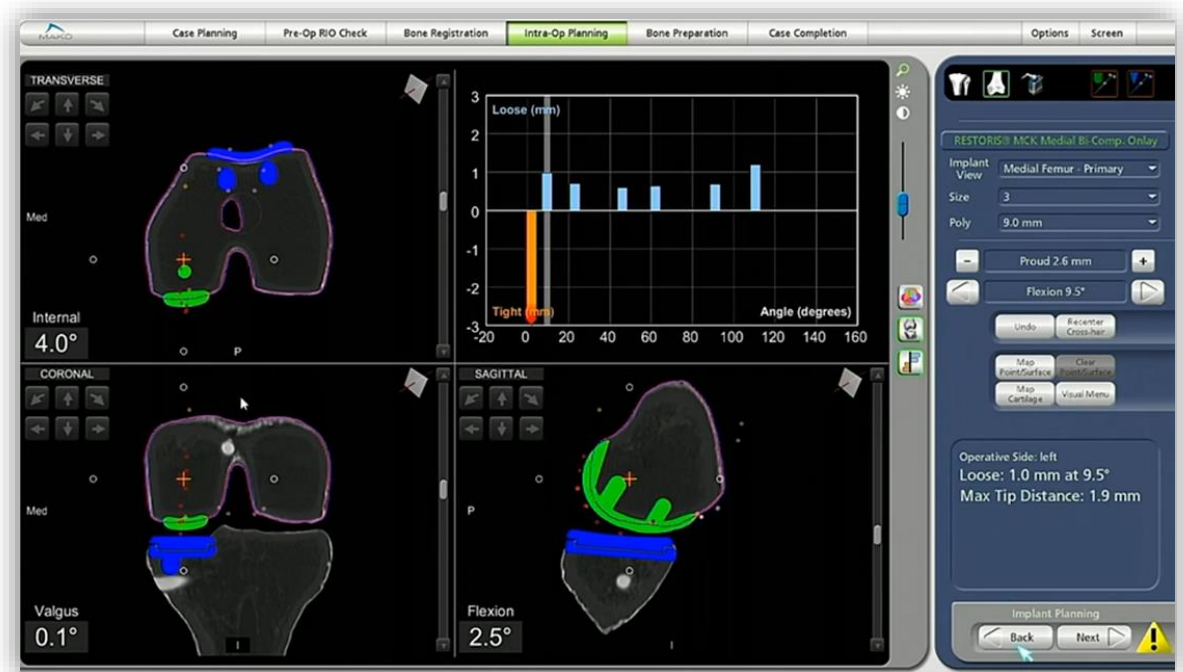


Implant tracking

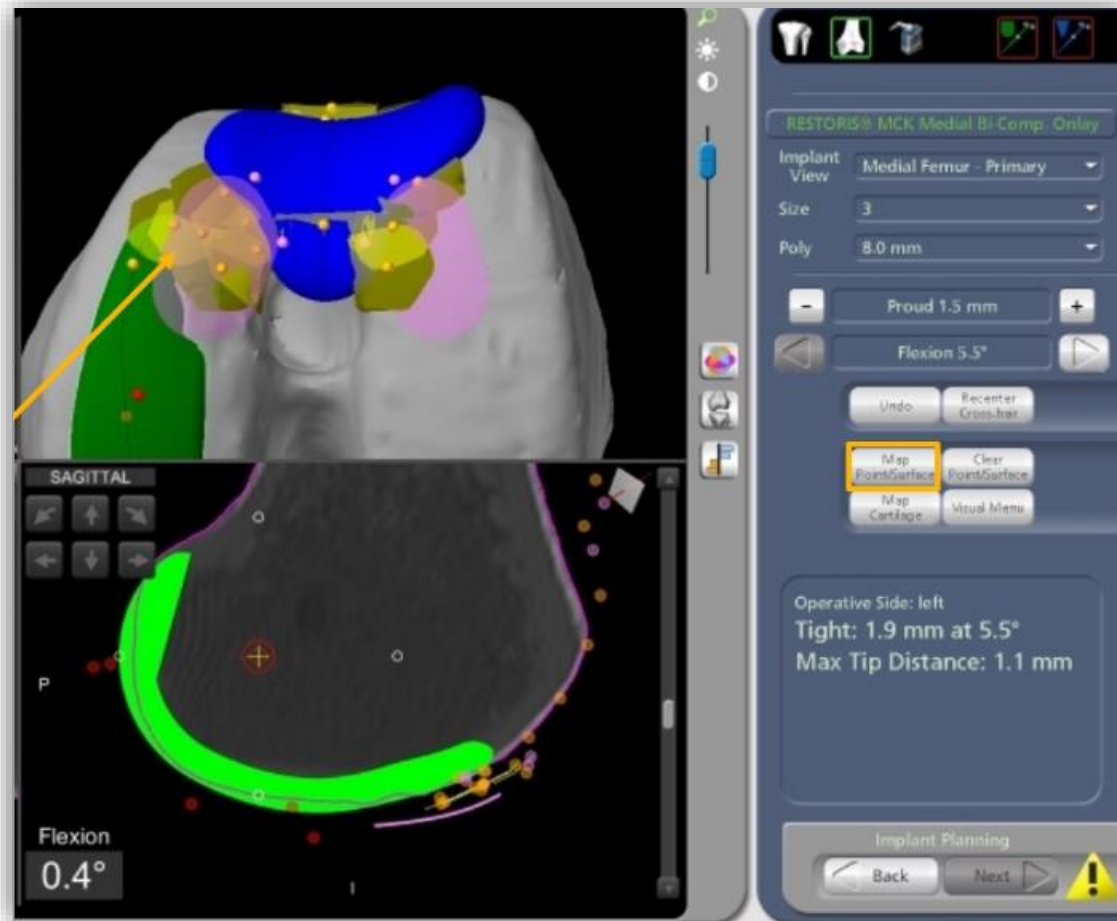
Gap balancing

Poses of the leg at a given knee flexion are captured throughout the range of motion (minimum of 4 poses). Mako software uses the captured poses to produce a graph.

After the poses are captured, the surgeon can make changes to the planned implants to balance the graph.



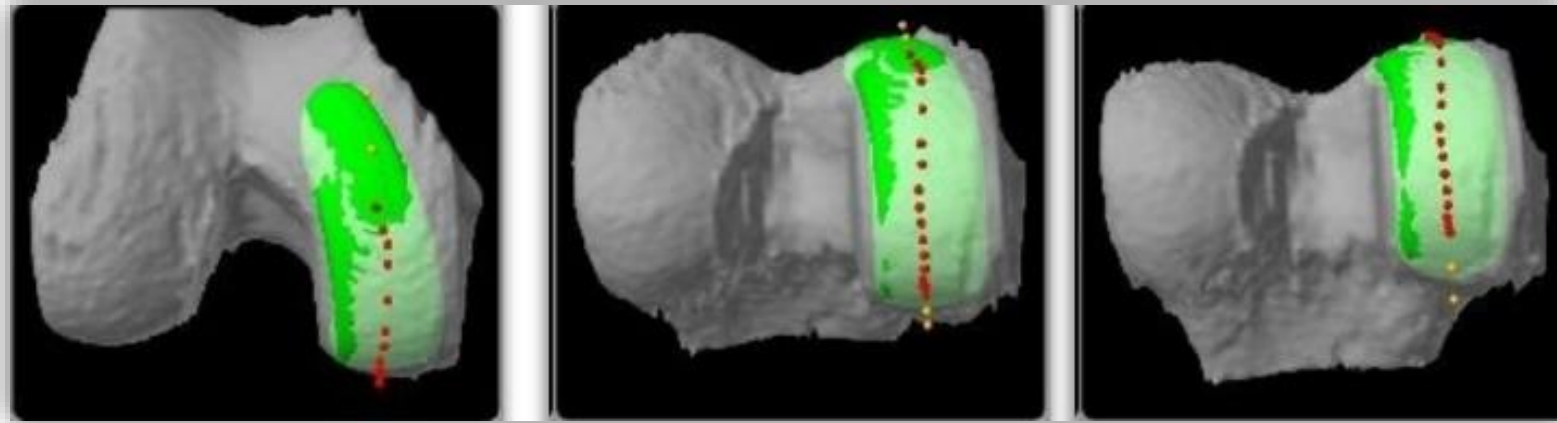
Cartilage mapping



Cartilage mapping helps ensure there is a smooth transition for the patella as it tracks from the trochlear groove onto the femoral component.

Surgeon uses green probe to map the patient's cartilage along the anterior tip of the femoral component.

Implant tracking



The purpose of tracking is to confirm the femoral and tibial implants are tracking on the center of each other to avoid edge loading.

Tracking points allow the surgeon to see where the center of the tibial component is tracking relative to the femoral implant throughout the range of motion, based on the captured poses.

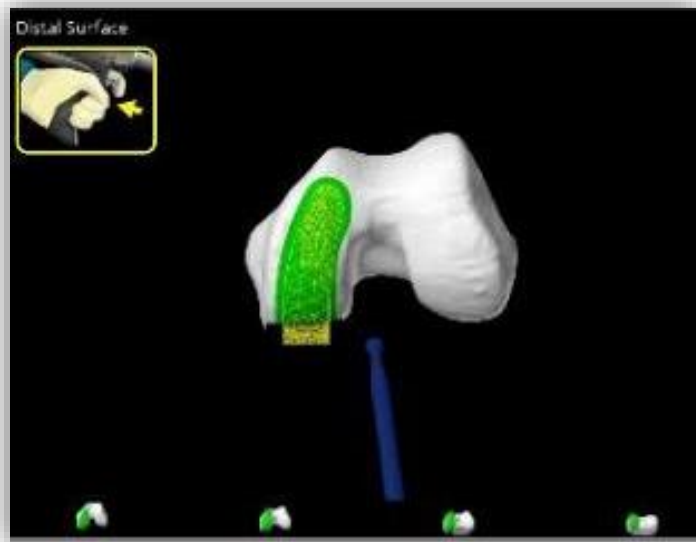
Bone Preparation with AccuStop™

**Mako Partial Knee
SmartRobotics™**

Cut less^{1,2*}

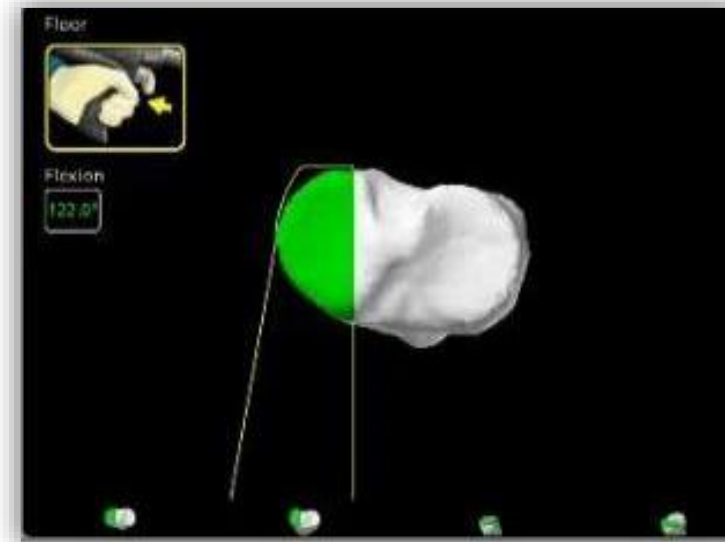
AccuStop™ haptic technology

The Mako Partial Knee SmartRobotics™ application has AccuStop™ haptic technology, which creates a virtual boundary that helps the surgeon in executing both the tibial and femoral bone resections to plan.



Burr-only workflow

Burr used for all cuts



Planar workflow

Saw used for posterior femur and tibial plateau
Burr used for remainder of cuts and tibial wall

*For the Mako Partial Knee application, “cut less” refers to greater bone preservation as compared to manual surgery.^{1,2}

Mako Partial Knee

Bone preparation workflows



Burr-only workflow

Cut	Flexion angle >115	Motorized alignment
Femur surface		Not recommended
Femur keel		✓
Femur posts		✓
Tibia surface		✓
Tibia posts	✓	✓



Planar workflow

Cut	Flexion ≥115°	Motorized alignment	Cutting tool
Tibia floor		✓	Saw
Posterior femur	✓	✓	Saw
Femur distal surface		Not recommended	Burr
Femur keel		✓	Burr
Femur posts		✓	Burr
Tibia wall		✓	Burr
Tibia posts	✓	✓	Burr

Partial Knee

Clinical success

Mako Partial Knee has demonstrated...

- ✔ Restoris MCK continues to lead both usage and performance metrics with a **Best-in-Class revision rate of 4.1% at 5-years**³
- ✔ **More accurate** implant placement to plan and **55.4% less pain** from day 1 to week 8 postoperative compared to manual partial knees with Oxford in a randomized controlled trial^{4,5}
- ✔ **97% survivorship** at 5- to 6-year follow-up, which outperformed other large cohort studies (94.2%) and annual registries (93.1%)⁶
- ✔ **98% survivorship** at 10-year follow-up⁷



References

1. Hampp E, Chang TC, Pearle A. Robotic partial knee arthroplasty demonstrated greater bone preservation compared to robotic total knee arthroplasty. Poster presented at: Orthopaedic Research Society Annual Meeting; February 2-5, 2019; Austin, TX.
2. Banks SA. Haptic robotics enable a systems approach to design of a minimally invasive modular knee arthroplasty. *Am J Orthop (Belle Mead NJ)*. 2009;38(2 Suppl):23-27.
3. National Joint Replacement Registry. Hip, Knee & Shoulder Arthroplasty Annual Report 2022. Australian Orthopaedic Association; 2022.
4. Bell SW, Anthony I, Jones B, MacLean A, Rowe P, Blyth M. Improved Accuracy of Component Positioning with Robotic-Assisted Unicompartmental Knee Arthroplasty: Data from a Prospective, Randomized Controlled Study. *J Bone Joint Surg Am*. 2016;98(8):627-635. doi:10.2106/JBJS.15.00664
5. Blyth MJG, Anthony I, Rowe P, Banger MS, MacLean A, Jones B. Robotic-arm assisted versus conventional unicompartmental knee arthroplasty: exploratory secondary analysis of a randomised controlled trial. *Bone Joint Res*. 2017;6(11):631-639. doi:10.1302/2046-3758.611.BJR-2017-0060.R1
6. Kleeblad LJ, Borus T, Coon TM, Douchis J, Nguyen JT, Pearle AD., Midterm survivorship and patient satisfaction of robotic-arm assisted medial unicompartmental knee arthroplasty: a multicenter study. *J Arthroplasty*. 2018; 33(6):1719-1726. doi:10.1016/j.arth.2018.01.036
7. Vakharia RM, Law TY, Roche MW. Survivorship and patient satisfaction rates of robotic-assisted unicompartmental knee arthroplasty. Presented at: American Association of Hip and Knee Surgeons (AAHKS) Annual Meeting; November 5-8, 2020; Dallas, TX.

A surgeon must always rely on his or her own professional clinical judgment when deciding whether to use a particular product when treating a particular patient. Stryker does not dispense medical advice and recommends that surgeons be trained in the use of any particular product before using it in surgery.

The information presented is intended to demonstrate the breadth of Stryker's product offerings. A surgeon must always refer to the package insert, product label and/or instructions for use before using any of Stryker's products. Products may not be available in all markets because product availability is subject to the regulatory and/or medical practices in individual markets. Please contact your sales representative if you have questions about the availability of products in your area.

Stryker Corporation or its divisions or other corporate affiliated entities own, use or have applied for the following trademarks or service marks: AccuStop, Mako, Restoris, SmartRobotics, Stryker. All other trademarks are trademarks of their respective owners or holders.

Copyright © 2022 Stryker