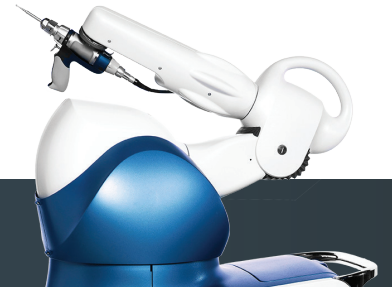




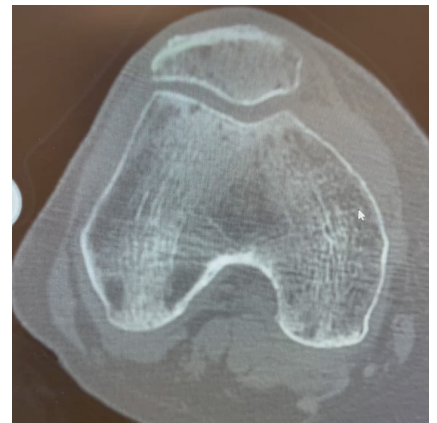
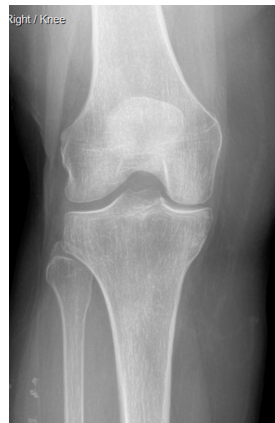Mako Partial Knee SmartRobotics™



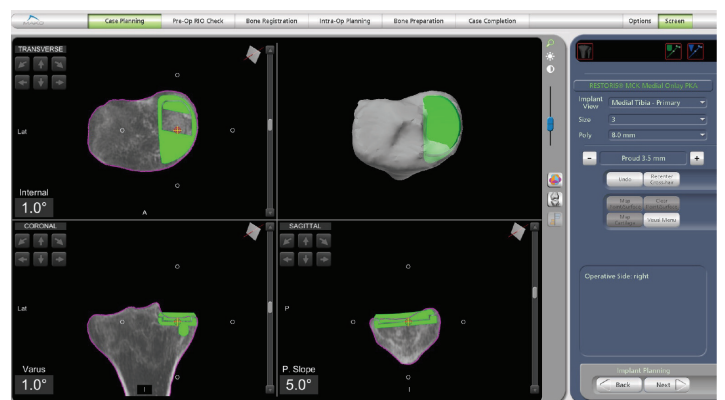
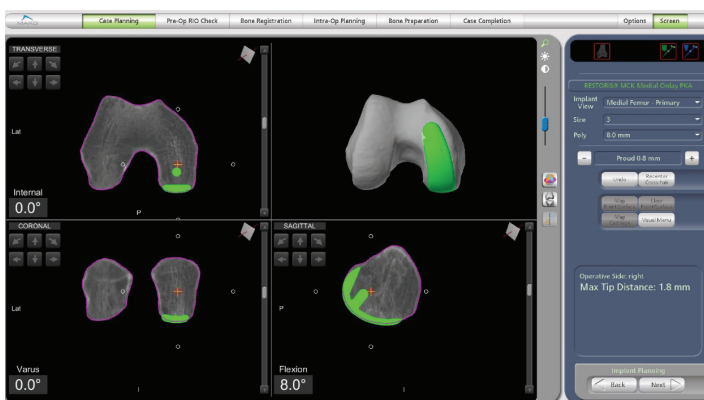
► Case review with Michael Morwood, M.D.

Patient history / Pre-op X-rays

- 67-year-old female presents with right knee pain
- Pre-op X-rays indicate significant medial joint space narrowing and retained lateral joint space
- No patellofemoral joint crepitus or pain
- Appropriate patellar tracking on imaging
- Decision made to proceed with medial partial knee



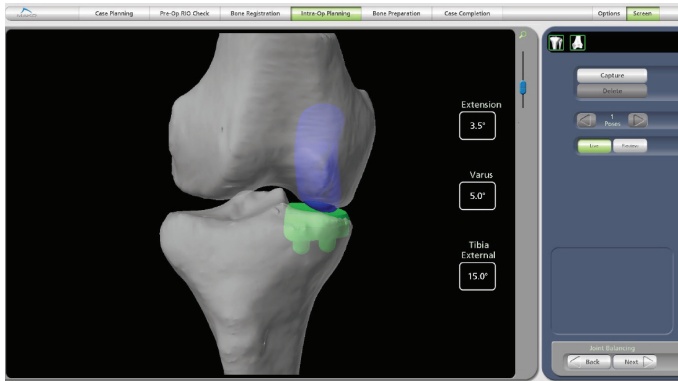
3D CT-based pre-planning



The starting CT-based pre-plan shows a size 3 femur and tibia with an 8.0mm poly. The femoral component is positioned 0.8mm proud with a flexion of 8.0° ensuring there is 75% coverage of the medial condyle and following the patient's natural bone curvature, as well as making sure there is no airballing or notching on the anterior or posterior tips.

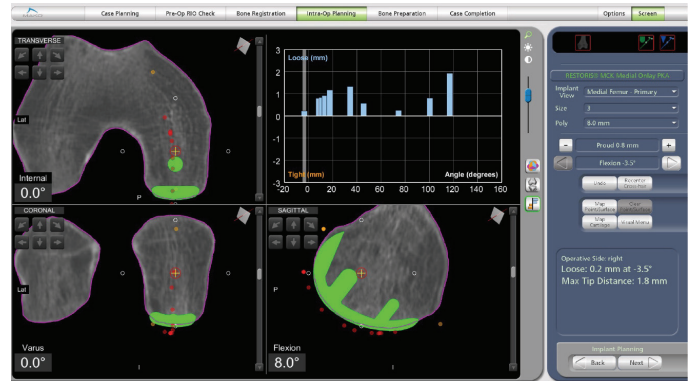
The tibial component was positioned with 1° of internal rotation, 1° of varus, p. slope of 5° and proudness of 3.5mm. The surgeon makes sure there is no implant overhang or impedance to tibial imminence and that the implant is following the natural curvature of bone.

Intra-op | Dynamic joint balancing



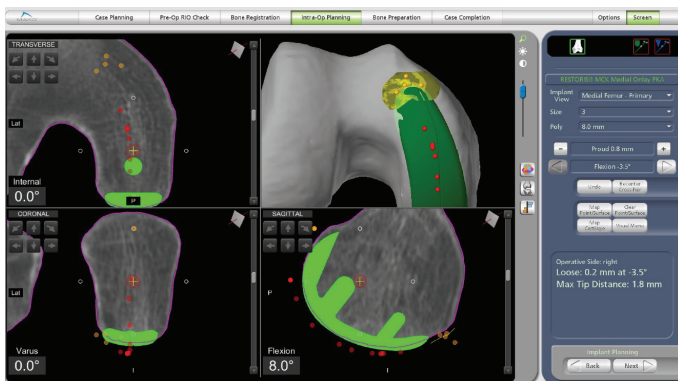
A minimum of four poses at a given knee flexion are captured throughout the range of motion. Here the surgeon is capturing the patient's baseline pose with no corrective force added.

Intra-op | Gap graph balancing



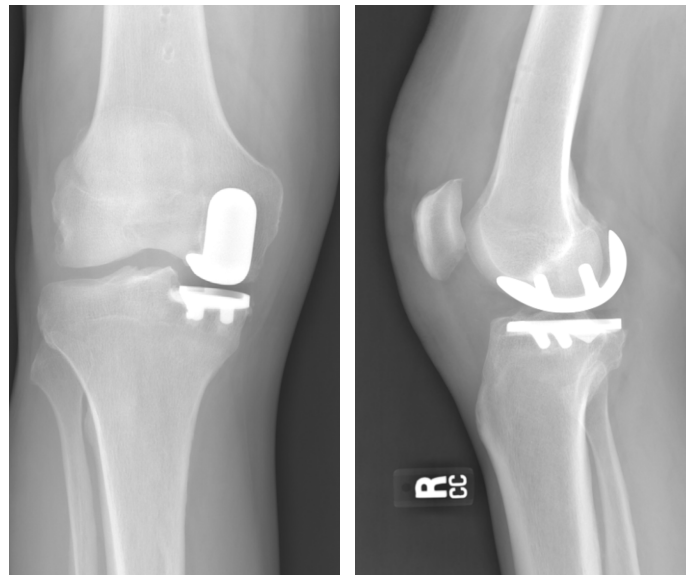
After poses are captured, a graph is produced displaying how tight or loose the knee will be at each pose based on the current implant plan. Additional changes to the plan can be made to balance the graph. Ideally, the graph should be planned 0-1.5mm loose for each pose.

Implant tracking and cartilage mapping



In the 3D model view, the red tracking points allow the surgeon to see where the center of the tibial component is tracking relative to the femoral implant, based on the captured poses. The surgeon maps cartilage by capturing various points along the anterior tip of the femoral component. The sagittal view is used to see the cartilage, which is displayed as a yellow line.

Post-op X-rays



Learn more about Mako Partial Knee SmartRobotics™



Dr. Morwood is a paid consultant of Stryker Orthopaedics. The opinions expressed by Dr. Morwood are those of Dr. Morwood and not necessarily those of Stryker. Individual experiences may vary. A surgeon must always rely on his or her own professional clinical judgment when deciding whether to use a particular product when treating a particular patient. Stryker does not dispense medical advice and recommends that surgeons be trained in the use of any particular product before using it in surgery.

The information presented is intended to demonstrate the breadth of Stryker's product offerings. A surgeon must always refer to the package insert, product label and/or instructions for use before using any of Stryker's products. Products may not be available in all markets because product availability is subject to the regulatory and/or medical practices in individual markets. Please contact your sales representative if you have questions about the availability of products in your area.

Stryker Corporation or its divisions or other corporate affiliated entities own, use or have applied for the following trademarks or service marks: AccuStop, Mako, SmartRobotics, Stryker, Triathlon. All other trademarks are trademarks of their respective owners or holders.